

L-Mesitran® Product Information

Mechanics

L-Mesitran Foam combines the polyurethane foam with L-Mesitran Soft gel. The polyurethane foam forms a cushioning layer that protects the wound from mechanical stress while allowing drainage to pass. Simultaneously, this physical barrier prevents pathogens from entering the wound, while it absorbs excess of wound fluid and maintains a moist wound environment. The addition of L-Mesitran Soft to a polyurethane foam results in a bioactive dressing and establishes a regenerative environment. The beneficial antimicrobial and healing properties of L-Mesitran Soft enhance the wound healing process. The introduction of MGH to the wound creates an osmotic effect which further stimulates the release of exudate that is subsequently absorbed and retained by the foam layer. The honey prevents re-opening of the freshly formed granulation tissue during dressing changes.

Ingredients

- Polyurethane foam
- L-Mesitran Soft

Indications

- Chronic wounds
- Pressure ulcers
- Superficial and partial thickness burns
- Venous, arterial and diabetic ulcers
- Fungating wounds
- Acute wounds
- Donor sites
- Surgical wounds
- Cuts and abrasions

Contra-indications

Do not use on individuals with a known sensitivity to the dressing or its components. The dressing should not be used on: full thickness burns, deep, narrow cavities or sinuses.

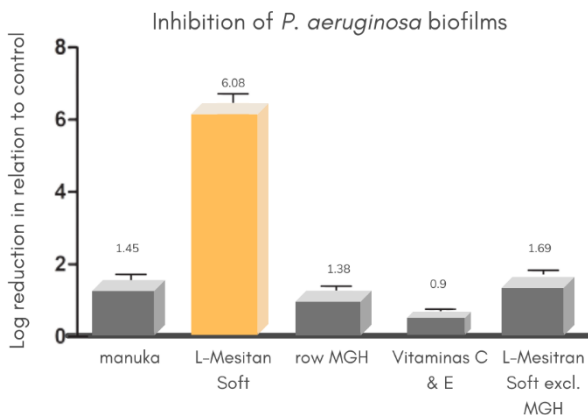


Figure 1. Synergistic activity of the L-Mesitran supplements.


Technical information

Film carrier: polyurethane foam
 Coating: L-Mesitran Soft
 Shelf life: 3 years
 CE classification: class IIb, sterile

Storage precautions

Store at room temperature 5°-25°C/41°-77°F. Store dry. Do not freeze. The storage conditions are detailed on the product cartons and tubes as symbols. Is sterile until opening.

Size	Box (primary packaging)	Box/case	Order code	Reference
10x10cm	10 pcs	20	MES-F 1010	712.10



L-Mesitran® Product Information

Case: Leg ulcer

A 57-year-old woman with diabetes presented to the hospital with a superficial wound on the leg.

Methods

The wound was treated with L-Mesitran Foam. The dressing changes were dependent on the amount of exudate. The first dressing change was after 2 days and the last two changes after one week. Five L-Mesitran Foam dressings were used to achieve the presented results.

Results

Previously the infected wound was treated with povidone iodine and silver dressing with no healing for a 6 months period. Since there were only local signs of infection, no systemic antibiotics were provided. Already after one dressing (Figure 2B), the sloughy tissue almost completely disappeared, and odour and pain levels strongly decreased. After 9 days of MGH treatment (Figure 2E), reepithelialisation and formation of granulation tissue clearly progressed, which continued over the next days (Figure 2F and 2G, day 12 and 16, respectively). After just 23 days, the wound was completely closed (Figure 2H).

Discussion

In combination with the foam dressing, L-Mesitran promotes the absorption of exudate by its osmotic activity. The attracted wound fluid will subsequently be absorbed by the hydrophilic L-Mesitran Foam dressing that has a high capacity to absorb and retain fluid. The Medical Grade Honey forms an important nutrient source for the proliferating skin cells and stimulates wound healing. The combination of L-Mesitran Soft with a foam dressing is a novelty that can help the healing of a wide variety of exuding wounds.

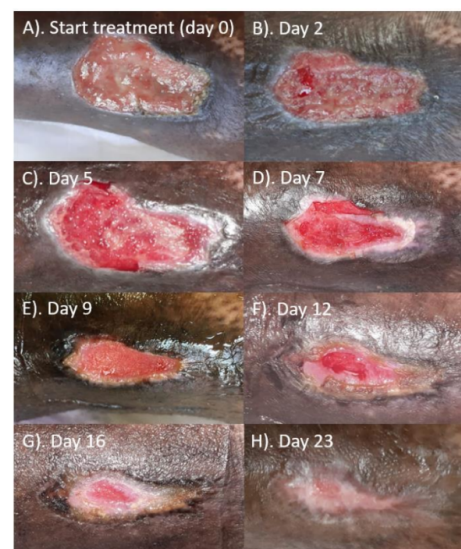


Figure 2. Wound healing progress.

References

1. Boekema BK, Pool L et al. The effect of a honey-based gel and silver sulphadiazine on bacterial infections of in vitro burn wounds. *Burns*. 2013;39(4):754-759.
2. Chatzoulis G, Chatzoulis K et al. Salvage of an infected titanium mesh in a large incisional ventral hernia using medicinal honey and vacuum-assisted closure: a case report and literature review. *Hernia*.2012;16(4):475-479.
3. Smaropoulos E, Cremers NA. Medical grade honey for the treatment of pediatric abdominal wounds: a case series. *J Wound Care*. 2020;29(2):94-99.
4. Smaropoulos E, Cremers NAJ. Treating severe wounds in pediatrics with medical grade honey: A case series. *Clin Case Rep*. 2020;8(3):469-476.
5. Smaropoulos E, Cremers NAJ. Medical grade honey for the treatment of extravasation-induced injuries in preterm neonates – a case series. *Advances in Neonatal Care*. 2020;in press.
6. Haynes SJ, Callaghan R. Properties of honey: its mode of action and clinical outcomes. *Wounds UK*.2011;7(1):50-57.
7. Mandel HH, Sutton GA et al. Intralesional application of medical grade honey improves healing of surgically treated lacerations in horses. *Equine Vet J*.2020;52(1):41-45.
8. Cremers N, Belas A et al. In vitro antimicrobial efficacy of two medical-grade honey formulations against common high-risk methicillin-resistant staphylococci and *Pseudomonas* spp. pathogens. *Vet Dermatol*.2020;31(2):90-96.
9. Hermanns R, Cremers NAJ et al. Sweet relief: determining the antimicrobial activity of medical grade honey against vaginal isolates of *Candida Albicans*. *JFungi (Basel)*. 2019;5(3).
10. Oliveira AMP, Devesa JSP et al. In vitro efficacy of honey-based gel against canine clinical isolates of *Staphylococcus pseudintermedius* and *Malasseziapachydermatis*. *Vet Dermatol*. 2018;29(3):180-e165.
11. de Groot T, Janssen T et al. Antifungal activity of medical-grade honey formulation against *CandidaAuris*. *J Fungi (Basel)*. 2021;7(1).
12. Holubová A, Chlupáčová L et al. Medical-grade honey as an alternative treatment for antibiotics in non-healing wounds—a prospective case series. *Antibiotics (Basel)*. 2021;10(8):918.
13. Naik PP, Mossialos D et al. Medical-grade honey outperforms conventional treatments for healing cold sores—a clinical study. *Pharmaceuticals (Basel)*.2021;14(12).
14. Nair HKR, Tatavilis N et al. Medical-grade honey kills antibiotic-resistant bacteria and prevents amputation in diabetics with infected ulcers: A prospective case series. *Antibiotics (Basel)*. 2020;9(9).
15. Pleeing CCF, Coenye T et al. Synergistic antimicrobial activity of supplemented medical-grade honey against *Pseudomonas Aeruginosa* biofilm formation and eradication. *Antibiotics*. 2020;9(12):866.
16. Gustafsson K, Tatz AJ et al. Intra-incisional medical-grade honey decreases the prevalence of incisional infection in horses undergoing colic surgery: a prospective randomized controlled study. *Equine Vet J*. 2020.
17. Smaropoulos E, Cremers NAJ. The pro-healing effects of medical-grade honey are supported by a pediatric case series. *Complement Ther Med*. 2019;45:14-18.
18. Du Toit DF, Page BJ. An in vitro evaluation of the cell toxicity of honey and silver dressings. *J WoundCare*. 2009;18(9):383-389.
19. Postmes T, van den Bogaard AE et al. Honey for wounds, ulcers, and skin graft preservation. *Lancet*.1993;341(8847):756-757.
20. Rossiter K, Cooper AJ et al. Honey promotes angiogenic activity in the rat aortic ring assay. *J WoundCare*. 2010;19(10):440, 442-446.
21. Nwabudike LC, Maruhashi E. Patient education, self-care, and medical grade honey—managing a diabetic ulcer. *Wounds International*. 2017;8(4):40-43.
22. Postmes T, van den Bogaard AE et al. The sterilization of honey with cobalt 60 gamma radiation: a study of honey spiked with spores of *Clostridium Botulinum*and *Bacillus Subtilis*. *Experientia*. 1995;51(9-10):986-989.
23. Postmes T. Speeding up the healing of burns with honey. *Bee Products*, edited by Mizrahi and LenskyPlenum Press, New York: 57-63. 1996:57-63.
24. Hermanns R, Mateescu C et al. Defining the standards for medical grade honey. *Journal of apicultural research*. 2020;59(2):125-135.
25. Zbucnea A. Honey, Food and Medicine: Scientificrationale and practical efficiency in external administration of medicinal honey for wound healing. *Journal of Agricultural Science and Technology B*. 2017;7:206-219.