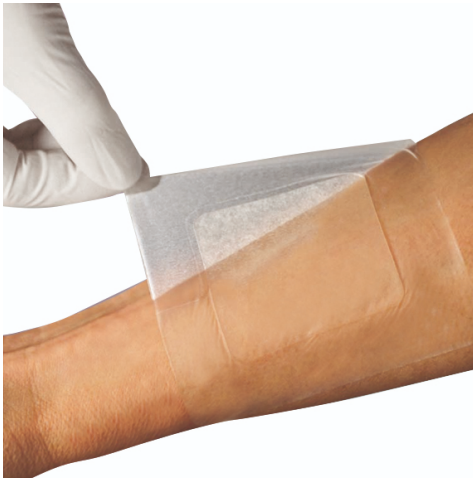

L-Mesitran® Product Information

Mechanics

Border is an antibacterial, hydro-active, low-adherence, honey-containing dressing for use on acute and chronic wounds. The honey-hydrogel pad donates moisture to re-hydrate dry tissue and is also able to absorb low to high levels of exudate to help maintain a moist environment conducive to healing. The film backing provides the dressing with bacterial barrier properties. Border kills most bacteria, including stant strains e.g. MRSA. It also prevents infection and quickly neutralizes wound odours. The product cleanses/debrides the wound, creates a moist wound healing environment, and optimizes wound healing. It draws fluid from surrounding tissues, facilitates autolysis of necrotic and devitalised material, promotes epithelization and reduces scarring. The gel does not adhere to the wound. L-Mesitran has no influence on blood glucose levels. The product has a cooling effect, which is helpful (with e.g. burns).



Ingredients

- 30% Medical Grade Honey
- Acrylic polymer gel
- Water with a polyurethane film backing

Indications

- Chronic wounds
- Pressure ulcers
- Superficial and partial thickness burns
- Venous, arterial and diabetic ulcers
- Fungating wounds
- Acute wounds
- Donor sites
- Surgical wounds
- Cuts and abrasions

Contra-indications

Do not use on individuals with a known sensitivity to the dressing or its components. The dressing should not be used on: full thickness burns, deep, narrow cavities or sinuses.


Technical information

Film carrier:	polyurethane film
Gel:	polymeric hydrogel infused with MGH
Shelf life:	3 years
CE classification:	class IIb

Storage precautions

Store at room temperature 5°-25°C/41°-77°F. Store dry. Do not freeze. The storage conditions are detailed on the product cartons and tubes as symbols. Is sterile until opening.

Size	Box (primary packaging)	Box/case	Order code	Reference
10x10cm	10 pcs	20	MES-B 1010	512.10



L-Mesitran® Product Information

BORDER

Case: Diabetic foot, Gram-positive bacilli

A 65 years old male was diagnosed 4 years prior with Diabetes Type 2. The patient accidentally kicked a piece of wood and had a wound on the lateral aspect of the heel of his left foot as a result. Before presenting to the clinic, the wound did not heal for 4 weeks..

Methods

After cleaning the wound, L-Mesitran Ointment was applied directly to the wound. This was combined with cotton fiber dressings, calcium alginates, foam, or L-Mesitran Border.

Results

At the start, the wound was slightly malodorous, which disappeared after a few days. On May 18th, the wound size was reduced by 40% in less than two weeks. In this case, a gram-positive colonized diabetic foot was treated successfully with only the honey-based ointment and L-Mesitran Border.

Discussion

In the evaluation study the L-Mesitran products demonstrated:

- that wound infections were rapidly cleared;
- that additional antibiotics were not necessary;
- to prevent eminent (partial) DM foot amputation;
- to quickly debride wounds;
- to reduce wound size rapidly.

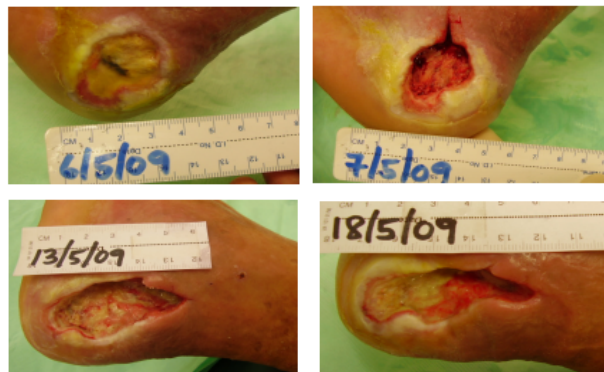


Figure 1. Wound healing progress.

References

1. Boekema BK, Pool L et al. The effect of a honey based gel and silver sulphadiazine on bacterial infections of in vitro burn wounds. *Burns*. 2013;39(4):754-759.
2. Chatzoulis G, Chatzoulis K et al. Salvage of an infected titanium mesh in a large incisional ventral hernia using medicinal honey and vacuum-assisted closure: a case report and literature review. *Hernia*. 2012;16(4):475-479.
3. Smaropoulos E, Cremers NA. Medical grade honey for the treatment of paediatric abdominal wounds: a case series. *J Wound Care*. 2020;29(2):94-99.
4. Smaropoulos E, Cremers NAJ. Treating severe wounds in pediatrics with medical grade honey: A case series. *Clin Case Rep*. 2020;8(3):469-476.
5. Smaropoulos E, Cremers NAJ. Medical grade honey for the treatment of extravasation-induced injuries in preterm neonates – a case series. *Advances in Neonatal Care*. 2020;in press.
6. Haynes SJ, Callaghan R. Properties of honey: its mode of action and clinical outcomes. *Wounds UK*. 2011;7(1):50-57.
7. Mandel HH, Sutton GA et al. Intralesional application of medical grade honey improves healing of surgically treated lacerations in horses. *Equine Vet J*. 2020;52(1):41-45.
8. Cremers N, Belas A et al. In vitro antimicrobial efficacy of two medical grade honey formulations against common high-risk methicillin-resistant staphylococci and Pseudomonas spp. pathogens. *Vet Dermatol*. 2020;31(2):90-96.
9. Hermans R, Cremers NAJ et al. Sweet relief: determining the antimicrobial activity of medical grade honey against vaginal isolates of Candida Albicans. *J Fungi (Basel)*. 2019;5(3).
10. Oliveira AMP, Devesa JSP et al. In vitro efficacy of a honey-based gel against canine clinical isolates of Staphylococcus pseudintermedius and Malassezia pachydermatis. *Vet Dermatol*. 2018;29(3):180-e165.
11. de Groot T, Janssen T et al. Antifungal activity of a medical-grade honey formulation against Candida Auris. *J Fungi (Basel)*. 2021;7(1).
12. Holubová A, Chlupáčová L et al. Medical-grade honey as an alternative treatment for antibiotics non-healing wounds—a prospective case series. *Antibiotics (Basel)*. 2021;10(8):918.
13. Naik PP, Mossialos D et al. Medical-grade honey outperforms conventional treatments for healing cold sores—a clinical study. *Pharmaceuticals (Basel)*. 2021;14(12).
14. Nair HKR, Tatavilis N et al. Medical-grade honey kills antibiotic-resistant bacteria and prevents amputation in diabetics with infected ulcers: A prospective case series. *Antibiotics (Basel)*. 2020;9(9).
15. Pleeing CCF, Coenye T et al. Synergistic antimicrobial activity of supplemented medical-grade honey against Pseudomonas Aeruginosa biofilm formation and eradication. *Antibiotics*. 2020;9(12):866.
16. Gustafsson K, Tatz AJ et al. Intra-incisional medical grade honey decreases the prevalence of incisional infection in horses undergoing colic surgery: a prospective randomised controlled study. *Equine Vet J*. 2020.
17. Smaropoulos E, Cremers NAJ. The pro-healing effects of medical grade honey supported by a pediatric case series. *Complement Ther Med*. 2019;45:14-18.
18. Du Toit DF, Page BJ. An in vitro evaluation of the cell toxicity of honey and silver dressings. *J Wound Care*. 2009;18(9):383-389.
19. Postmes T, van den Bogaard AE et al. Honey for wounds, ulcers, and skin graft preservation. *Lancet*. 1993;341(8847):756-757.
20. Rossiter K, Cooper AJ et al. Honey promotes angiogenic activity in the rat aortic ring assay. *J Wound Care*. 2010;19(10):440, 442-446.
21. Nwabudike LC, Maruhashi E. Patient education, self care and medical grade honey—managing a diabetic ulcer. *Wounds International*. 2017;8(4):40-43.
22. Postmes T, van den Bogaard AE et al. The sterilization of honey with cobalt 60 gamma radiation: a study of honey spiked with spores of Clostridium Botulinum and Bacillus Subtilis. *Experientia*. 1995;51(9-10):986-989.
23. Postmes T. Speeding up the healing of burns with honey. *Bee Products*, edited by Mizrahi and Lensky Plenum Press, New York: 57-63. 1996:57-63.
24. Hermans R, Mateescu C et al. Defining the standards for medical grade honey. *Journal of Apicultural Research*. 2020;59(2):125-135.
25. Zbucsea A. Honey, Food and Medicine: Scientific rationale and practical efficiency in external administration of medical honey for wound healing. *Journal of Agricultural Science and Technology B*. 2017;7:206-219.